

# Extracorporeal Cardiac Shock Wave Therapy Markedly Ameliorates Ischemia-Induced Myocardial Dysfunction in Pigs in Vivo

Takahiro Nishida, MD; Hiroaki Shimokawa, MD; Keiji Oi, MD; Hideki Tatewaki, MD; Toyokazu Uwatoku, MD; Kohtaro Abe, MD; Yasuharu Matsumoto, MD; Noriyoshi Kajihara, MD; Masataka Eto, MD; Takehisa Matsuda, PhD; Hisataka Yasui, MD; Akira Takeshita, MD; Kenji Sunagawa, MD

**Background**—Prognosis of ischemic cardiomyopathy still remains poor because of the lack of effective treatments. To develop a noninvasive therapy for the disorder, we examined the in vitro and vivo effects of extracorporeal shock wave (SW) that could enhance angiogenesis.

**Methods and Results**—SW treatment applied to cultured human umbilical vein endothelial cells significantly upregulated mRNA expression of vascular endothelial growth factor and its receptor Flt-1 in vitro. A porcine model of chronic myocardial ischemia was made by placing an ameroid constrictor at the proximal segment of the left circumflex coronary artery, which gradually induced a total occlusion of the artery with sustained myocardial dysfunction but without myocardial infarction in 4 weeks. Thereafter, extracorporeal SW therapy to the ischemic myocardial region (200 shots/spot for 9 spots at  $0.09 \text{ mJ/mm}^2$ ) was performed ( $n=8$ ), which induced a complete recovery of left ventricular ejection fraction ( $51\pm 2\%$  to  $62\pm 2\%$ ), wall thickening fraction ( $13\pm 3\%$  to  $30\pm 3\%$ ), and regional myocardial blood flow ( $1.0\pm 0.2$  to  $1.4\pm 0.3 \text{ mL} \cdot \text{min}^{-1} \cdot \text{g}^{-1}$ ) of the ischemic region in 4 weeks (all  $P<0.01$ ). By contrast, animals that did not receive the therapy ( $n=8$ ) had sustained myocardial dysfunction (left ventricular ejection fraction,  $48\pm 3\%$  to  $48\pm 1\%$ ; wall thickening fraction,  $13\pm 2\%$  to  $9\pm 2\%$ ) and regional myocardial blood flow ( $1.0\pm 0.3$  to  $0.6\pm 0.1 \text{ mL} \cdot \text{min}^{-1} \cdot \text{g}^{-1}$ ). Neither arrhythmias nor other complications were observed during or after the treatment. SW treatment of the ischemic myocardium significantly upregulated vascular endothelial growth factor expression in vivo.

**Conclusions**—These results suggest that extracorporeal cardiac SW therapy is an effective and noninvasive therapeutic strategy for ischemic heart disease. (*Circulation*. 2004;110:3055-3061.)

**Key Words:** angiogenesis ■ contractility ■ hibernation ■ ischemia ■ regional blood flow

Prognosis of ischemic cardiomyopathy without an indication for coronary intervention or coronary artery bypass grafting still remains poor because medication is the only therapy to treat the disorder.<sup>1</sup> Thus, it is imperative that an effective and noninvasive therapy for ischemic cardiomyopathy be developed. Although no medication or procedure used clinically has shown efficacy in replacing myocardial scar with functioning contractile tissue, it could be possible to improve the contractility of the hibernating myocardium by inducing angiogenesis.

It recently has been suggested that shock wave (SW) could enhance angiogenesis in vitro.<sup>2</sup> SW is a longitudinal acoustic wave, traveling with the speed in water of ultrasound through body tissue. It is a single pressure pulse with a short needle-like positive spike  $<1 \mu\text{s}$  in duration and up to 100 MPa in amplitude, followed by a tensile part of several

microseconds with lower amplitude.<sup>3</sup> SW is known to exert the “cavitation effect” (a micrometer-sized violent collapse of bubbles inside and outside the cells)<sup>3</sup> and recently has been demonstrated to induce localized stress on cell membranes that resembles shear stress.<sup>4</sup> If SW-induced angiogenesis could be reproduced in vivo, it would provide a unique opportunity to develop a new angiogenic therapy that would not require invasive procedures such as open-chest surgery or catheter intervention. Therefore, the present study was designed to examine the possible beneficial effects of SW on ischemia-induced myocardial dysfunction in a porcine model of chronic myocardial ischemia in vivo.

## Methods

This study was reviewed by the Committee on Ethics in Animal Experiments of Kyushu University and was carried out under the

Received May 5, 2003; de novo received June 2, 2004; accepted June 17, 2004.

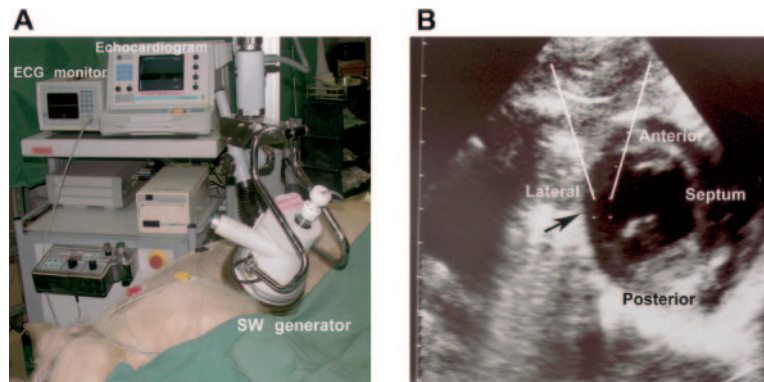
From the Departments of Cardiovascular Surgery (T.N., H.T., N.K., M.E., H.Y.), Cardiovascular Medicine (K.O., H.S., T.U., K.A., Y.M., A.T., K.S.), and Biomedical Engineering (T.M.), and the 21st Century COE Program on Lifestyle-Related Diseases (H.S., T.M.), Kyushu University Graduate School of Medical Sciences, Fukuoka, Japan.

Correspondence to Hiroaki Shimokawa, MD, PhD, Department of Cardiovascular Medicine, Kyushu University Graduate School of Medical Sciences, 3-1-1 Maidashi, Higashi-ku, Fukuoka 812-8582, Japan. E-mail shimo@cardiol.med.kyushu-u.ac.jp

© 2004 American Heart Association, Inc.

*Circulation* is available at <http://www.circulationaha.org>

DOI: 10.1161/01.CIR.0000148849.51177.97



**Figure 1.** Extracorporeal cardiac SW therapy in action in a pig chronically instrumented with an ameroid constrictor. A, The machine is equipped with a SW generator and in-line echocardiography. The SW generator is attached to the chest wall when used. B, The SW pulse is easily focused on the ischemic myocardium under the guidance of echocardiography (black arrow).

Guidelines for Animal Experiments of Kyushu University and the Law (No. 105) and Notification (No. 6) of the Japanese Government.

### Effect of SW on Human Umbilical Vein Endothelial Cells in Vitro

We purchased single-donor human umbilical vein endothelial cells (HUVECs) (Clonetics, Walkersville, Md) and cultured them in a complete endothelial medium (EBM-2 BulletKit, Clonetics). HUVECs were subcultured and used at passages 3 to 5 and were maintained in EBM-2. Twenty-four hours before the SW treatment, HUVECs ( $1 \times 10^5$ ) were resuspended in a 2-mL tube with EBM (Clonetics). We treated the HUVECs with 500 shots of SW at 4 different energy levels (0 [control], 0.02, 0.09, 0.18, and 0.35 mJ/mm<sup>2</sup>) and stored them for 24 hours in the same medium before RNA extraction.

### Ribonuclease Protection Assay

We analyzed equal amounts of mRNA by ribonuclease protection assay by means of the RiboQuant multiprobe template (PharMingen). Briefly, we hybridized RNA overnight with a <sup>32</sup>P-labeled RNA probe, which previously had been synthesized from the template set. We digested single-stranded RNA and free probe by ribonuclease A and T1. We then analyzed protected RNA on a 5% denaturing polyacrylamide gel. We analyzed several angiogenic factors, including vascular endothelial growth factor (VEGF) and its receptor, *fms*-like tyrosine kinase (Flt)-1, and angiopoietin and its receptor, tie-1, either by means of an NIH image or by means of autoradiography and subsequent quantification by densitometry (Alpha Innotech). For quantification, we normalized the signals for each sample of the blot with the corresponding signals of the housekeeping genes GAPDH and L32.

### Porcine Model of Chronic Myocardial Ischemia

A total of 28 domestic pigs (25 to 30 kg in body weight) were used in this study. We anesthetized the animals with ketamine (15 mg/kg IM) and maintained anesthesia with an inhalation of 1.5% isoflurane for implantation of an ameroid constrictor, SW treatment, and euthanization. We opened the chest, suspended the pericardium and the left atrial appendage, revealed the left circumflex coronary artery (LCx), and put an ameroid constrictor around the proximal LCx to gradually induce a total occlusion of the artery in 4 weeks without causing myocardial infarction.<sup>5,6</sup> We also confirmed histologically that no myocardial necrosis had developed in the present porcine model (data not shown). This model is widely used to examine the effect of an angiogenic therapy in the ischemic hibernating myocardium.<sup>5,6</sup>

### Extracorporeal Cardiac SW Therapy to Chronic Ischemic Myocardium

On the basis of the in vitro experiment, we applied a low energy of SW (0.09 mJ/mm<sup>2</sup>,  $\approx 10\%$  of the energy for the lithotripsy treatment) to 9 spots in the ischemic region (200 shots/spot) with the guidance of an echocardiogram equipped within a specially designed

SW generator (Storz Medical AG) (Figure 1A). We were able to focus SW in any part of the heart under the guidance of echocardiography (Figure 1B). We applied SW to the ischemic myocardium in an R-wave-triggered manner to avoid ventricular arrhythmias. We performed the SW treatment (n=8) at 4 weeks after the implantation of an ameroid constrictor 3 times within 1 week, whereas animals in the control group (n=8) received the same anesthesia procedures 3 times a week but without the SW treatment. Because the SW treatment only requires the gentle compression of the generator to the chest wall, it is unlikely that this handling itself enhances angiogenesis in the ischemic myocardium.

### Coronary Angiography and Left Ventriculography

After systemic heparinization (10 000 U/body), we performed coronary angiography and left ventriculography in a left oblique view with the use of a cineangiography system (Toshiba Medical). We semiquantitatively evaluated the extent of collateral flow to the LCx by the graded Rentrop score (0, no visible collateral vessels; 1, faint filling of side branches of the main epicardial vessel without filling the main vessel; 2, partial filling of the main epicardial vessel; 3, complete filling of the main vessel).<sup>7</sup> We also counted the number of visible coronary arteries in the LCx region. To compare the extent of collateral development at a given time, we selected the frame in which the whole left anterior descending coronary artery was first visualized.

### Echocardiographic Evaluation

We performed epicardial echocardiographic studies at ameroid implantation (baseline) and at 4 and 8 weeks after the implantation of the constrictor (Sonos 5500, Agilent Technology). We calculated wall thickening fraction (WTF) by using the following formula:  $WTF = 100 \times (\text{end-systolic wall thickness} - \text{end-diastolic wall thickness}) / \text{end-diastolic wall thickness}$ . We measured WTF when pigs were sedated, with and without dobutamine loading ( $15 \mu\text{g} \cdot \text{kg}^{-1} \cdot \text{min}^{-1}$ ). Dobutamine was infused continuously from the ear vein, and WTF was measured after the hemodynamic condition was stabilized (in  $\approx 5$  minutes).

### Measurement of Regional Myocardial Blood Flow

We evaluated regional myocardial blood flow (RMBF) with colored microspheres (Dye-Trak, Triton Technology) at ameroid implantation (baseline) and at 4 and 8 weeks after implantation.<sup>8</sup> We injected microspheres through the left atrium and aspirated a reference arterial blood sample from the descending aorta at a constant rate of 20 mL/min for 60 seconds using a withdrawal pump. We extracted microspheres from the left ventricular (LV) wall and blood samples by potassium hydroxide digestion, extracted the dyes from the spheres with dimethylformamide (200  $\mu\text{L}$ ), and determined their concentrations by spectrophotometry.<sup>8</sup> We calculated myocardial blood flow ( $\text{mL} \cdot \text{min}^{-1} \cdot \text{g}^{-1}$ ) of the endocardial and epicardial lateral LV wall (the LCx region).

### Analysis of Cardiac Enzymes

We measured serum concentrations of cardiac troponin T and creatinine kinase (CK)-MB by using chemiluminescence immuno-

assay before the SW treatment and at 4, 5 (2 hours after the SW treatment), and 8 weeks after ameroid implantation.

**Factor VIII Staining**

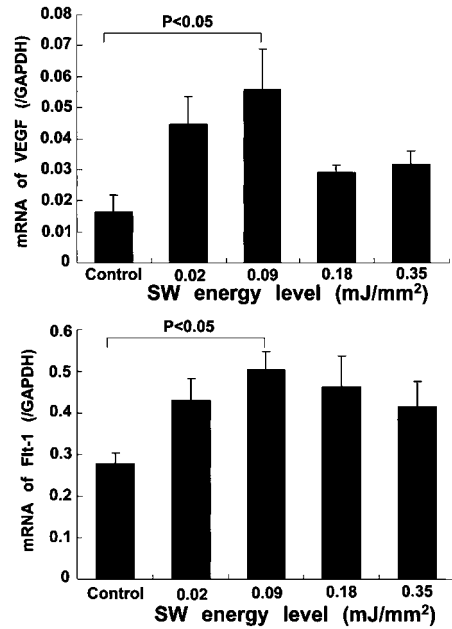
We treated paraffin-embedded sections with a rabbit anti-factor VIII antibody (N1505, Dako, Copenhagen, Denmark). We counted the number of factor VIII-positive cells in the endocardial and epicardial wall in 10 fields of the LCx region in each heart at 400× magnification.

**Real-Time Polymerase Chain Reaction**

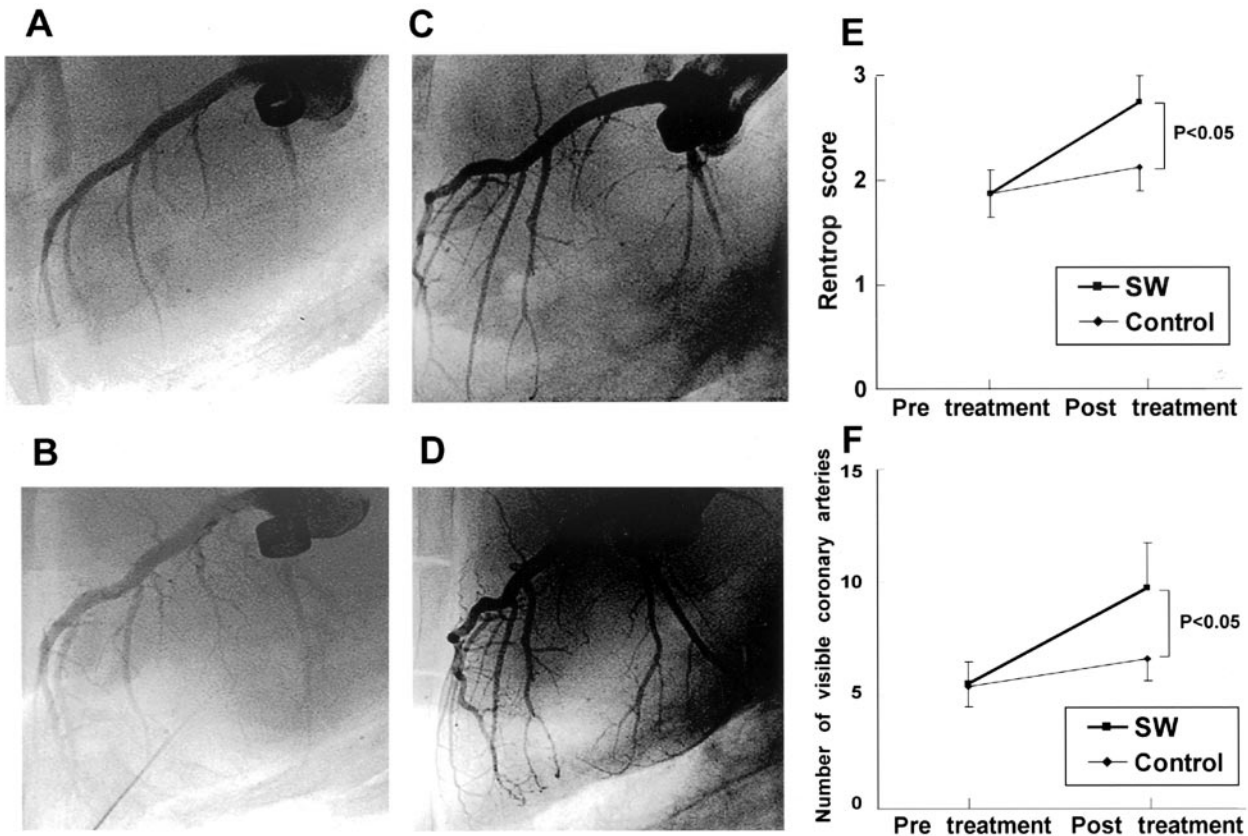
To examine the effect of SW treatment on the ischemic myocardium in vivo, the animals with an ameroid constrictor were euthanized 1 week after the SW treatment. Total RNA was isolated from rapidly frozen ischemic LV wall (LCx region) after 3 SW treatments and was reverse transcribed. Quantification of VEGF and its receptor Flt-1 was performed by amplification of cDNA with an ABI Prism 7000 real-time thermocycler.

**Western Blot Analysis for VEGF**

We performed Western blot analysis for VEGF. Western blot analysis for VEGF was performed with and without 3 SW treatments. Three sections from the ischemic LV wall (LCx region) were measured. The regions containing VEGF proteins were visualized by electrochemiluminescence Western blotting luminal reagent (Santa Cruz Biotechnology). The extent of the VEGF was normalized by that of β-actin.

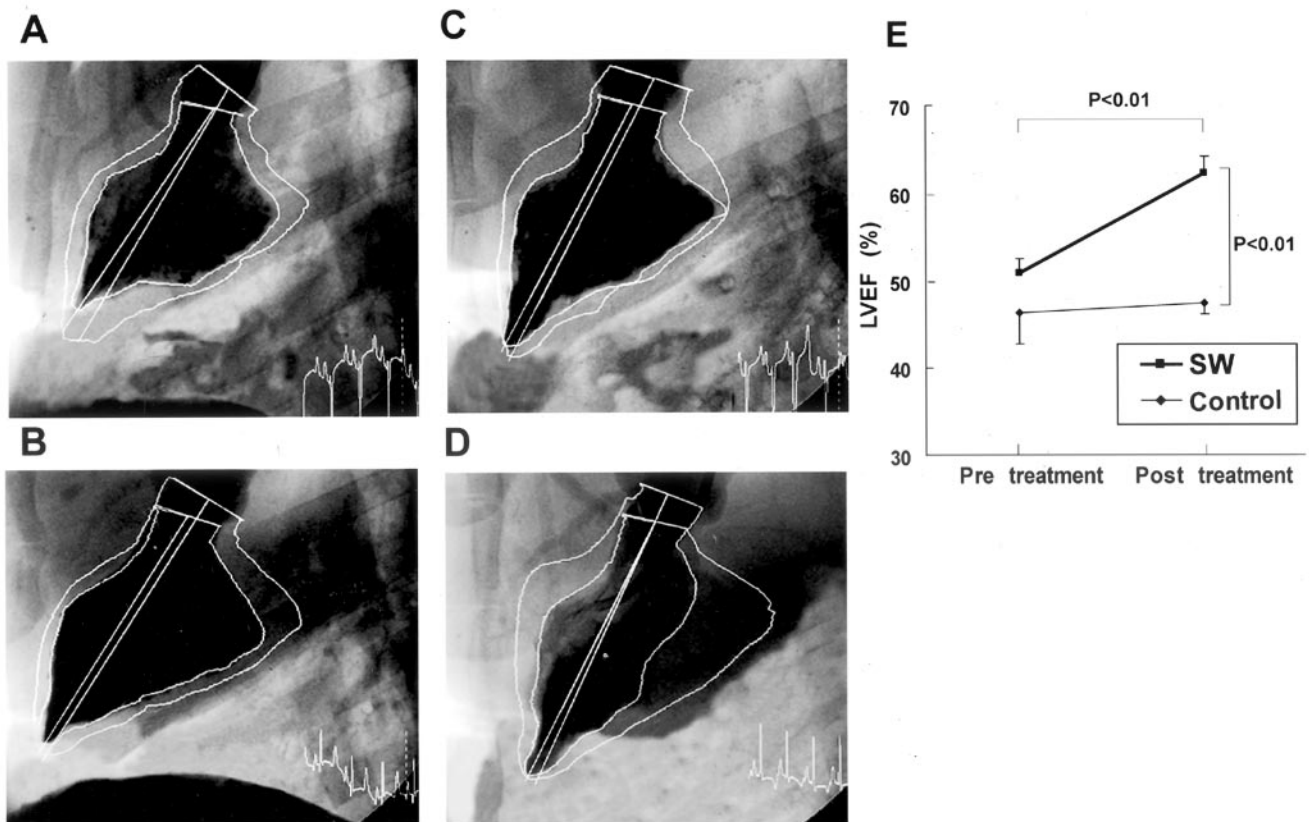


**Figure 2.** SW treatment upregulated mRNA expression of VEGF (A) and Flt-1 (B) in HUVECs in vitro with a maximum effect noted at 0.09 mJ/mm². Results are expressed as mean±SEM (n=10 each).



**Figure 3.** Extracorporeal cardiac SW therapy enhances coronary angiogenesis in vivo. A and C, Four weeks after the implantation of an ameroid constrictor, LCx was totally occluded and was perfused via collateral vessels with severe delay in both the control group (A) and the SW group (before SW therapy) (C). B and D, Four weeks after the first coronary angiography, no significant change in coronary vessels was noted in the control group (B), whereas a marked development of visible coronary vessels was noted in the SW group (D). E and F, Four weeks after the first coronary angiography, no significant increase in the Rentrop score (E) or visible coronary arteries from LCx (F) was noted in the control group, whereas increased Rentrop score and a marked development of visible coronary vessels were noted in the SW group. Results are expressed as mean±SEM (n=8 each).





**Figure 4.** Extracorporeal cardiac SW therapy improves ischemia-induced myocardial dysfunction in vivo. A and C, Four weeks after the implantation of an ameroid constrictor, LV wall motion of the LCx (posterolateral) region was reduced in both the control (A) and the SW group (before the SW therapy) (C). B and D, Four weeks after the first left ventriculography, no significant change in LV wall motion was noted in the control group (B), whereas marked recovery was noted in the SW group (D). E, The SW therapy normalized left ventricular ejection fraction in the SW group but not in the control group. Results are expressed as mean $\pm$ SEM (n=8 each).

### Statistical Analysis

Results are expressed as mean $\pm$ SEM. We determined statistical significance by analysis of variance for multiple comparisons. A value of  $P < 0.05$  was considered to be statistically significant.

### Results

#### Effect of SW on mRNA Expression of VEGF and Flt-1 in HUVECs

SW treatment significantly upregulated mRNA expression of VEGF and its receptor Flt-1 in HUVECs, with a maximum effect noted at 0.09 mJ/mm<sup>2</sup> (Figure 2).

#### Effects of Extracorporeal Cardiac SW Therapy on Angiogenesis and Ischemia-Induced Myocardial Dysfunction

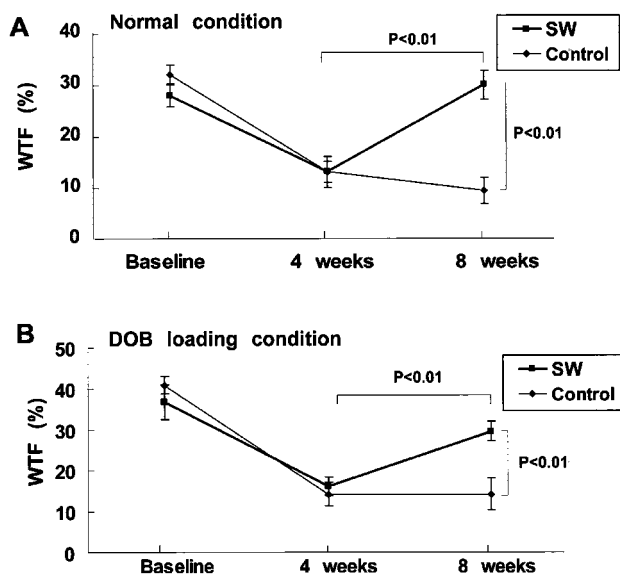
Four weeks after ameroid implantation, coronary angiography demonstrated a total occlusion of the LCx, which was perfused via collateral vessels with severe delay in both the control (Figure 3A) and the SW groups (Figure 3C). At 8 weeks after ameroid implantation (4 weeks after SW therapy), the SW group (Figure 3D), but not the control group (Figure 3B), had a marked development of coronary collateral vessels in the ischemic LCx region, an increased Rentrop score (Figure 3E), and an increased number of visible coronary arteries in the region (Figure 3F). Similarly, at 4 weeks, left ventriculography demonstrated an impaired left

ventricular ejection fraction in both groups (Figure 4A, 4C, and 4E), whereas at 8 weeks, left ventricular ejection fraction was normalized in the SW group but remained impaired in the control group (Figure 4B, 4D, and 4E).

#### Effects of Extracorporeal Cardiac SW Therapy on Regional Myocardial Function and Myocardial Blood Flow

We serially measured WTF of the LCx region (lateral wall of the LV) by epicardial echocardiography. At 4 weeks, we observed a significant reduction in WTF (%) in both groups (13 $\pm$ 2 in the control group and 13 $\pm$ 3 in the SW group; Figure 5A). At 8 weeks, however, the SW treatment markedly improved WTF in the SW group (30 $\pm$ 3) but not in the control group (9 $\pm$ 2) under control conditions (Figure 5A). Under dobutamine-loading conditions, which mimicked exercise conditions, WTF was further reduced at 4 weeks after the ameroid implantation in both groups (16 $\pm$ 3 in the control and 18 $\pm$ 2 in the SW groups), however, at 8 weeks, WTF was again markedly ameliorated only in the SW group (31 $\pm$ 2) but not in the control group (16 $\pm$ 4) (Figure 5B).

At 4 weeks, RMBF in the endocardium and epicardium (mL  $\cdot$  min<sup>-1</sup>  $\cdot$  g<sup>-1</sup>) was equally decreased in both groups (1.0 $\pm$ 0.3 and 0.9 $\pm$ 0.2 in the control group and 1.0 $\pm$ 0.2 and 0.9 $\pm$ 0.2 in the SW group, respectively). The SW treatment again improved RMBF in the endocardium (0.6 $\pm$ 0.1 in the

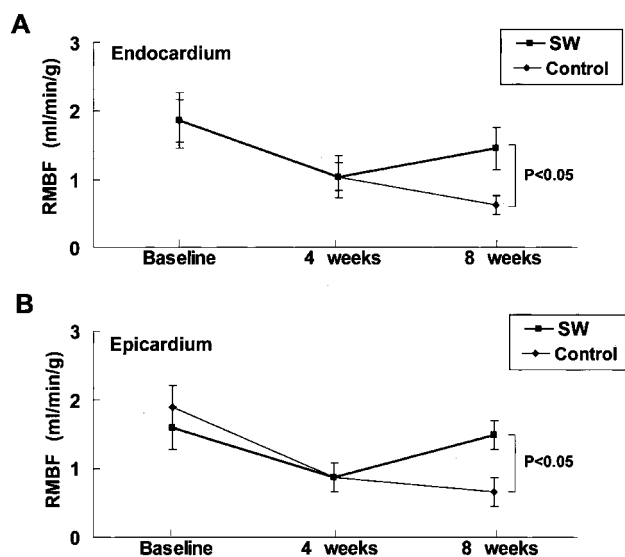


**Figure 5.** Extracorporeal cardiac SW therapy improves regional myocardial function in vivo. SW therapy induced a complete recovery of WTF of the ischemic lateral wall under control conditions (A) and under dobutamine (DOB) loading conditions (B). Results are expressed as mean $\pm$ SEM (n=8 each).

control group and  $1.4\pm 0.3$  in the SW group,  $P<0.05$ ; Figure 6A) as well as in the epicardium ( $0.7\pm 0.2$  in the control group and  $1.5\pm 0.2$  in the SW group,  $P<0.05$ ; Figure 6B).

### Effects of Extracorporeal Cardiac SW Therapy on Capillary Density and VEGF Expression in the Ischemic Myocardium

Factor VIII staining showed that the number of factor VIII-positive capillaries was increased in the SW group compared with the control group (Figure 7A and 7B). Quantitative analysis demonstrated that the number of capil-



**Figure 6.** Extracorporeal cardiac SW therapy improves RMBF in vivo. SW therapy significantly increased RMBF, assessed by colored microspheres in both the endocardium (A) and the epicardium (B). Results are expressed as mean $\pm$ SEM (n=8 each).

laries was significantly higher in the SW group in both the endocardium ( $840\pm 26$  in the control group and  $1280\pm 45$  in the SW group,  $P<0.05$ ; Figure 7C) and the epicardium ( $820\pm 30$  in the control group and  $1200\pm 22$  in the SW group,  $P<0.05$ ; Figure 7D). RT-PCR analysis and Western blotting demonstrated a significant upregulation of VEGF mRNA expression ( $8.0\pm 6$  in the control group and  $32\pm 8$  in the SW group,  $P<0.05$ ; Figure 8A) and protein expression (2.23-fold increase in the SW groups,  $P<0.05$ ; Figure 8B) after the SW treatment to the ischemic myocardium in vivo.

### Side Effects of Extracorporeal Cardiac SW Therapy

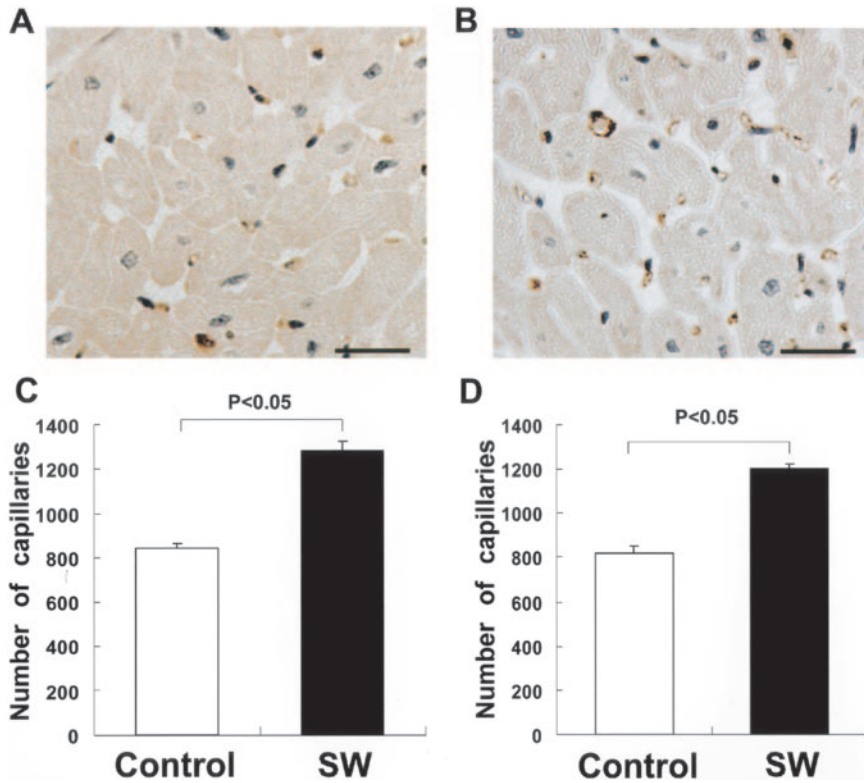
All animals treated with the SW therapy were alive and showed no arrhythmias as assessed by 24-hour Holter ECG during and after the treatment (n=3; data not shown). There also was no myocardial cell damage as assessed by serum concentrations of CK-MB (ng/mL); the values before the SW treatment and at 4, 5 (2 hours after the SW treatment), and 8 weeks after the ameroid implantation were  $5.0\pm 0.6$ ,  $6.2\pm 0.5$ ,  $5.5\pm 0.2$ , and  $7.1\pm 0.9$  in the control group and  $5.1\pm 0.2$ ,  $7.7\pm 0.6$ ,  $6.1\pm 0.6$ , and  $6.4\pm 0.4$  in the SW group, respectively (n=6 each). The serum concentrations of troponin T were not detected in most cases in both groups. No significant differences were noted in hemodynamic variables (eg, heart rate or blood pressure) between the 2 groups (data not shown).

### Discussion

The novel finding of the present study is that the extracorporeal cardiac SW therapy enhances angiogenesis in the ischemic myocardium and normalizes myocardial function in a porcine model of chronic myocardial ischemia in vivo. To the best of our knowledge, this is the first report that demonstrates the potential usefulness of extracorporeal cardiac SW therapy as a noninvasive treatment of chronic myocardial ischemia.

### Extracorporeal Cardiac SW Therapy as a Novel Strategy for Ischemic Cardiomyopathy

Because of the poor prognosis of ischemic cardiomyopathy,<sup>1,9</sup> it is crucial to develop an alternative therapy for ischemia-induced myocardial dysfunction. To accomplish effective angiogenesis, it is mandatory to upregulate potent angiogenesis ligands, such as VEGF, and their receptors.<sup>9,10</sup> Furthermore, in the clinical setting, the goal for the treatment of ischemic cardiomyopathy should include not only enhancement of angiogenesis but also recovery of ischemia-induced myocardial dysfunction. In the present study, we were able to demonstrate that SW treatment (1) normalized global and regional myocardial functions as well as RMBF of the chronic ischemic region without any adverse effects in vivo, (2) increased vascular density in the SW-treated region, and (3) enhanced mRNA expression of VEGF and its receptor Flt-1 in HUVECs in vitro and VEGF production in the ischemic myocardium in vivo. Thus, SW-induced upregulation of the endogenous angiogenic system may offer a novel and promising noninvasive strategy for the treatment of ischemic heart disease.

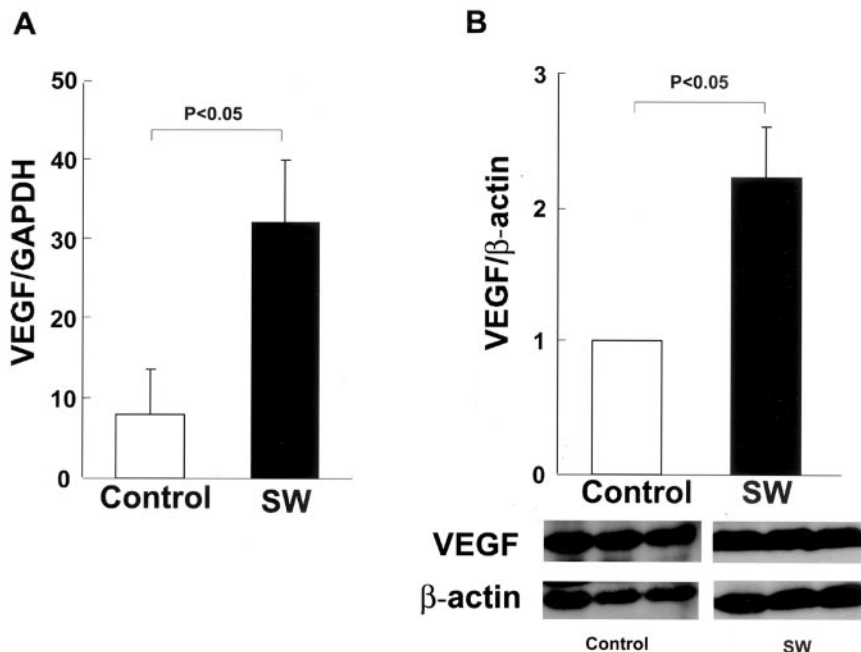


**Figure 7.** Extracorporeal cardiac SW therapy increases the density of factor VIII-positive capillaries in the ischemic myocardium. A and B, Factor VIII staining of the LCx region from the control (A) and the SW group (B). Scale bar represents 20  $\mu$ m. C and D, Capillary density was significantly greater in the SW group (SW) than in the control group (Control) in both the endocardium (C) and the epicardium (D). Results are expressed as mean  $\pm$  SEM (n=6 each).

### Advantages of Extracorporeal Cardiac SW Therapy

Recent attempts to enhance angiogenesis in the ischemic organs include gene therapy and bone marrow cell transplantation therapy. The main purpose of gene therapy is to induce overexpression of a selected angiogenic ligand (eg, VEGF) that leads to angiogenesis in the ischemic region. Although phase 1 trials of gene transfer of plasmid DNA encoding VEGF demonstrated safety and clinical benefit for the treatment of ischemic limb and

heart,<sup>11-13</sup> gene therapy for ischemic cardiomyopathy is still at a preclinical stage. Bone marrow cell transplantation therapy, which depends on adult stem cell plasticity, also may be a useful strategy for angiogenesis because endothelial progenitor cells could be isolated from circulating mononuclear cells in humans and could be shown to be incorporated into neovascularization.<sup>14</sup> However, the need for invasive delivery of those cells to the ischemic myocardium may severely limit its usefulness in clinical situations.



**Figure 8.** SW treatment upregulated mRNA (A) and protein (B) expression of VEGF in the ischemic myocardium (n=5 each).



A major advantage of the extracorporeal cardiac SW therapy over these 2 strategies is shown by the fact that it is quite noninvasive and safe, without any adverse effects. If necessary, we could repeatedly treat patients (even outpatients) with SW therapy because no surgery, anesthesia, or even catheter intervention is required for the treatment. This is an important factor in determining the clinical usefulness of angiogenic therapies in patients with ischemic cardiomyopathy. Thus, the extracorporeal cardiac SW therapy appears to be an applicable and noninvasive treatment for ischemic heart disease. Indeed, the SW treatment itself already has been clinically established as an effective and safe treatment for lithotripsy and chronic plantar fasciitis.<sup>15,16</sup> Our present results indicate that SW therapy, at  $\approx 10\%$  of the energy needed for lithotripsy treatment, is effective for in vivo angiogenesis in the ischemic heart.

### Mechanisms for SW-Induced Angiogenesis

When a SW hits tissue, cavitation (a micrometer-sized violent collapse of bubbles) is induced by the first compression by the positive pressure part and the expansion with the tensile part of a SW.<sup>3</sup> Because the physical forces generated by cavitation are highly localized, SW could induce localized stress on cell membranes, as altered shear stress affects endothelial cells.<sup>17</sup> Recent reports have demonstrated the biochemical effects of SW, including hyperpolarization and Ras activation,<sup>18</sup> nonenzymatic nitric oxide synthesis,<sup>19</sup> and induction of stress fibers and intercellular gaps.<sup>20</sup> Although precise mechanisms for the SW-induced biochemical effects remain to be examined, these mechanisms may be involved in the underlying mechanisms for SW-induced angiogenesis. Indeed, Wang et al<sup>21</sup> reported that SW induces angiogenesis of the Achilles tendon–bone junction in dogs.

We were able to demonstrate that the SW treatment upregulated mRNA expression of VEGF and its receptor Flt in HUVECs in vitro and VEGF expression in the ischemic myocardium in vivo. Because the VEGF-Flt system is essential in initiating vasculogenesis and/or angiogenesis,<sup>22</sup> this effect of SW could explain, at least in part, the underlying mechanisms for SW-induced angiogenesis. It should be noted, however, that we showed only the upregulation of VEGF and Flt and that the effect of SW on signal transduction after receptor–ligand interaction still remains to be clarified. In addition, we need to fully elucidate the mechanisms for the SW-induced complete recovery of ischemia-induced myocardial dysfunction, although the increased myocardial blood flow caused by the SW treatment appears to play a primary role for the improved myocardial function. Further studies are required to determine the precise molecular mechanism for SW-induced angiogenesis and recovery of myocardial function.

In summary, we were able to demonstrate that noninvasive extracorporeal cardiac SW therapy effectively increases RMBF and normalizes ischemia-induced myocardial dysfunction without any adverse effects. Thus, extracorporeal cardiac SW therapy may be an effective, safe, and noninvasive therapy for ischemic cardiomyopathy.

### Acknowledgments

This study was supported in part by a grant from the 21st Century COE Program and grants-in-aid from the Japanese Ministry of

Education, Culture, Sports, Science, and Technology, Tokyo, Japan (Nos. 12032215, 12470158, 12877114, 13307024, 13557068), and the Japanese Ministry of Health, Labor, and Welfare, Tokyo, Japan. We thank Dr Ernest H. Marlinghaus, Storz Medical AG, Switzerland, for valuable discussion about our study, and Prof S. Mohri at the Center of Biomedical Research, Kyushu University Graduate School of Medical Sciences, for cooperation in this study.

### References

- Jessup M, Brozena S. Heart failure. *N Engl J Med*. 2003;348:2007–2018.
- Gutersohn A, Caspari G. Shock waves upregulate vascular endothelial growth factor mRNA in human umbilical vascular endothelial cells. *Circulation*. 2000;102(suppl):18.
- Apfel RE. Acoustic cavitation: a possible consequence of biomedical uses of ultrasound. *Br J Cancer*. 1982;45(suppl):140–146.
- Maisonhaute E, Prado C, White PC, et al. Surface acoustic cavitation understood via nanosecond electrochemistry, part III: shear stress in ultrasonic cleaning. *Ultrason Sonochem*. 2002;9:297–303.
- O’Konski MS, White FC, Longhurst J, et al. Ameroid constriction of the proximal left circumflex coronary artery in swine: a model of limited coronary collateral circulation. *Am J Cardiovasc Pathol*. 1987;1:69–77.
- Roth DM, Maruoka Y, Rogers J, et al. Development of coronary collateral circulation in left circumflex ameroid–occluded swine myocardium. *Am J Physiol*. 1987;253:H1279–1288.
- Rentrop KP, Cohen M, Blanke H, et al. Changes in collateral channel filling immediately after controlled coronary artery occlusion by an angioplasty balloon in human subjects. *J Am Coll Cardiol*. 1985;5:587–592.
- Prinzen FW, Bassingthwaite JB. Blood flow distributions by microsphere deposition methods. *Cardiovasc Res*. 2000;45:13–21.
- Carmeliet P, Ferreira V, Breier G, et al. Abnormal blood vessel development and lethality in embryos lacking a single VEGF allele. *Nature*. 1996;380:435–439.
- Ferrara N, Carver-Moore K, Chen H, et al. Heterozygous embryonic lethality induced by targeted inactivation of the VEGF gene. *Nature*. 1996;380:439–442.
- Isner JM, Pieczek A, Schainfeld R, et al. Clinical evidence of angiogenesis after arterial gene transfer of phVEGF165 in patient with ischaemic limb. *Lancet*. 1996;348:370–374.
- Baumgartner I, Pieczek A, Manor O, et al. Constitutive expression of phVEGF165 after intramuscular gene transfer promotes collateral vessel development in patients with critical limb ischemia. *Circulation*. 1998;97:1114–1123.
- Losordo DW, Vale PR, Symes JF, et al. Gene therapy for myocardial angiogenesis: initial clinical results with direct myocardial injection of phVEGF165 as sole therapy for myocardial ischemia. *Circulation*. 1998;98:2800–2804.
- Asahara T, Murohara T, Sullivan A, et al. Isolation of putative progenitor endothelial cells for angiogenesis. *Science*. 1997;275:964–966.
- Auge BK, Preminger GM. Update on shock wave lithotripsy technology. *Curr Opin Urol*. 2002;12:287–290.
- Weil LS Jr, Roukis TS, Weil LS, et al. Extracorporeal shock wave therapy for the treatment of chronic plantar fasciitis: indications, protocol, intermediate results, and a comparison of results to fasciotomy. *J Foot Ankle Surg*. 2002;41:166–172.
- Fisher AB, Chien S, Barakat AI, et al. Endothelial cellular response to altered shear stress. *Am J Physiol*. 2001;281:L529–L533.
- Wang FS, Wang CJ, Huang HJ, et al. Physical shock wave mediates membrane hyperpolarization and Ras activation for osteogenesis in human bone marrow stromal cells. *Biochem Biophys Res Commun*. 2001;287:648–655.
- Gotte G, Amelio E, Russo S, et al. Short-time non-enzymatic nitric oxide synthesis from L-arginine and hydrogen peroxide induced by shock waves treatment. *FEBS Lett*. 2002;520:153–155.
- Seidl M, Steinbach P, Worle K, et al. Induction of stress fibres and intercellular gaps in human vascular endothelium by shock-waves. *Ultrasonics*. 1994;32:397–400.
- Wang CJ, Huang HY, Pai CH. Shock wave–enhanced neovascularization at the tendon–bone junction: an experiment in dogs. *J Foot Ankle Surg*. 2002;41:16–22.
- Millauer B, Wizigmann-Voos S, Schnurch H, et al. High affinity VEGF binding and developmental expression suggest Flk-1 as a major regulator of vasculogenesis and angiogenesis. *Cell*. 1993;72:835–846.

## Extracorporeal Cardiac Shock Wave Therapy Markedly Ameliorates Ischemia-Induced Myocardial Dysfunction in Pigs in Vivo

Takahiro Nishida, Hiroaki Shimokawa, Keiji Oi, Hideki Tatewaki, Toyokazu Uwatoku, Kohtarō Abe, Yasuharu Matsumoto, Noriyoshi Kajihara, Masataka Eto, Takehisa Matsuda, Hisataka Yasui, Akira Takeshita and Kenji Sunagawa

*Circulation*. 2004;110:3055-3061; originally published online November 1, 2004;  
doi: 10.1161/01.CIR.0000148849.51177.97

*Circulation* is published by the American Heart Association, 7272 Greenville Avenue, Dallas, TX 75231  
Copyright © 2004 American Heart Association, Inc. All rights reserved.  
Print ISSN: 0009-7322. Online ISSN: 1524-4539

The online version of this article, along with updated information and services, is located on the  
World Wide Web at:

<http://circ.ahajournals.org/content/110/19/3055>

**Permissions:** Requests for permissions to reproduce figures, tables, or portions of articles originally published in *Circulation* can be obtained via RightsLink, a service of the Copyright Clearance Center, not the Editorial Office. Once the online version of the published article for which permission is being requested is located, click Request Permissions in the middle column of the Web page under Services. Further information about this process is available in the [Permissions and Rights Question and Answer](#) document.

**Reprints:** Information about reprints can be found online at:  
<http://www.lww.com/reprints>

**Subscriptions:** Information about subscribing to *Circulation* is online at:  
<http://circ.ahajournals.org/subscriptions/>